

# Cytomegalovirus triggering autoimmune hepatitis: case report and literature review

Neil Vyas<sup>1</sup>, Rafael Ching Companioni<sup>2</sup>, James Nguyen<sup>1</sup>, Hassan Alkhawam<sup>1</sup>, Robert Sogomonian<sup>1</sup>, Ishan Patel<sup>1</sup>, Joel Baum<sup>2</sup>, Aaron Walfish<sup>2</sup>

<sup>1</sup>Department of Internal Medicine, Elmhurst Hospital Center, Elmhurst NY, USA.

<sup>2</sup>Department of Gastroenterology, Elmhurst Hospital Center, Elmhurst NY, USA.

Correspondence to: Neil Vyas, E-mail: Neil.vyas@mssm.edu

Received May 22, 2016. Accepted August 5, 2016

## Abstract

Cytomegalovirus (CMV) is considered to play a role in triggering autoimmune hepatitis (AIH). It is difficult to diagnose autoimmune hepatitis because its presentation can be acute, severe, asymptomatic or chronic. Diagnosis requires multiple findings and exclusions of similar diseases. When excluding, viral etiologies are part of the differential, which in this case is CMV. If a trigger is required to set off a sequence of events leading to autoimmune hepatitis in these predisposed individuals, viruses are among the most likely candidates. In this study, a case of a 54 year-old female who presents with new onset of jaundice, associated with abdominal distension, lower extremity edema and 10 pound weight gain is reported. The autoimmune workup of the patient was significant for an elevated antibodies to nuclei (ANA) titer, anti-smooth muscle ab titer and a significant increase in immunoglobulins, specifically IgG. Interestingly, CMV Ab IgM was positive as well as CMV Ab IgG. A liver biopsy was performed which showed heavy infiltration with lymphoplasmacytic inflammatory cells, interface hepatitis, bridging necrosis and fibrosis. These pathologic and laboratory findings led us to a definitive diagnosis of AIH Type 1. In the setting of positive CMV IgG and IgM ab titers, we suggest that the trigger for AIH in this case was a preceding CMV infection. Patient improved with combination of azathioprine and corticosteroid therapy despite intermittent flares of the patient's AIH.

**KEYWORDS:** Autoimmune hepatitis (AIH), cytomegalovirus (CMV), liver disease

## Introduction

Autoimmune hepatitis (AIH) is a chronic inflammatory condition of the liver with unknown etiology. It has a population prevalence of 0.01–0.02% and typically occurs in females.<sup>[1]</sup> AIH causes chronic hepatocellular inflammation and necrosis within the liver lobules. This is a response to the body's own immune system attacking liver surface membrane antigens<sup>[1]</sup> leading to cirrhosis and possibly liver failure.<sup>[1,2,4,5]</sup> AIH is divided into two types: Type 1 AIH is characterized by circulating antibodies to nuclei (ANA) or smooth muscle (ASMA) and

Type 2 AIH is characterized by the presence of antibodies to liver or kidney microsomes (ALKM-1) and/or to a liver cytosol antigen (ALC-1).<sup>[1,3,6]</sup> ALKM-1 serve as a serologic marker for AIH type 2, and it reacts with recombinant antigen cytochromic monooxygenase P450. Type 1 is typically characterized as 70% female with peak incidence between ages 16 and 30 years old. Type 2 is rare overall and 20 times less frequent than type 1.<sup>[1]</sup> At the time of diagnosis, there was 25% of cirrhosis, characterized by high titer (>1:80), ANA (homogenous or speckled pattern) reactive with chromatin and occasionally dsDNA and ASMA, reactive with F-actin microfilaments. Histologically, the liver biopsy reveals a chronic necroinflammatory disorder characterized by nonspecific findings such as portal mononuclear cell infiltrate, periportal lesion (sometimes referred to as piecemeal necrosis or interface hepatitis), bile duct changes, destructive, and non destructive cholangitis and ductopenia present in 25% of patients, plasma cell infiltrate and liver fibrosis.<sup>[7]</sup> The causes of AIH are still unclear, however viruses are suggested in playing a role in predisposed individuals. In this study, a unique case of CMV triggering autoimmune hepatitis is presented.

### Access this article online

Website: <http://www.ijmsph.com>

DOI: 10.5455/ijmsph.2017.22052016564

Quick Response Code:



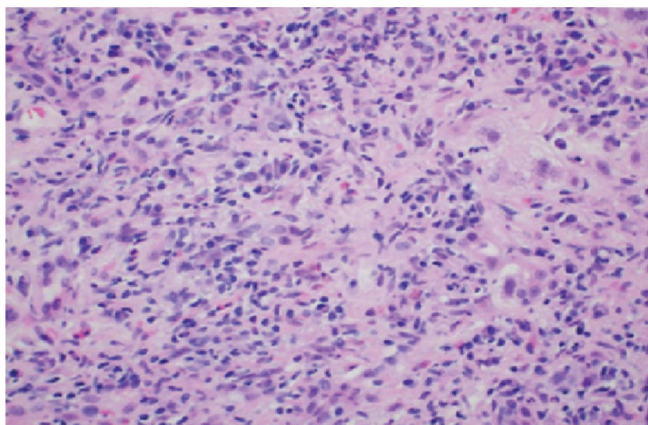
International Journal of Medical Science and Public Health Online 2017. © 2017 Neil Vyas. This is an Open Access article distributed under the terms of the Creative Commons Attribution 4.0 International License (<http://creativecommons.org/licenses/by/4.0/>), allowing third parties to copy and redistribute the material in any medium or format and to remix, transform, and build upon the material for any purpose, even commercially, provided the original work is properly cited and states its license.

## Case Report

Patient is a 54 year-old female who presents with new onset of jaundice, associated with abdominal distension, lower extremity edema and 10 pound weight gain. The patient has no history of intravenous drug use, blood transfusions, any new sexual partners in over 8 years or a family history of liver disease. The physical examination was remarkable for spider angiomata, icteric sclera, ascites, and bilateral lower extremity edema.

The results of the biochemical analysis of the blood were the following: liver enzymes were all elevated, ALP 162 U/L, GGT 65 U/L, AST 154 U/L, ALT 72 U/L. The patient's autoimmune workup was significant for an elevated ANA titer of 1:640, anti-smooth muscle ab titer 1:40, and a significant increase in immunoglobulins (Ig), specifically IgG which was 4100 mg/dL. Interestingly, CMV Ab IgM was positive at 36.6 u/mL as well as CMV Ab IgG, which was positive at >10.00 u/mL. The rest of the work up including hepatitis A, B, C, HIV, HSV, Epstein Barr virus (EBV), alpha1 antitrypsin, ceruloplasmin, iron level, ferritin, and antimitochondrial ab (was unremarkable). A liver biopsy was performed which showed heavy infiltration with lymphoplasmacytic inflammatory cells, interface hepatitis, bridging necrosis, and fibrosis (see Figure 1 and 2). These pathologic and laboratory findings led to a definitive diagnosis of autoimmune hepatitis (AIH) Type 1. In the setting of positive CMV IgG and IgM ab titers, we suggest that the trigger for AIH in this case was a preceding CMV infection.

Patient improved with the following treatment with combination of azathioprine and corticosteroid therapy. Patient improved with combination of azathioprine and corticosteroid therapy despite intermittent flares of AIH. The patient has tapered off steroids in a period of 2 months but continues to use azathioprine. Patients liver enzymes and total bilirubin have downtrended while immunoglobulins have worsened. However, clinically improved ascites and jaundice.



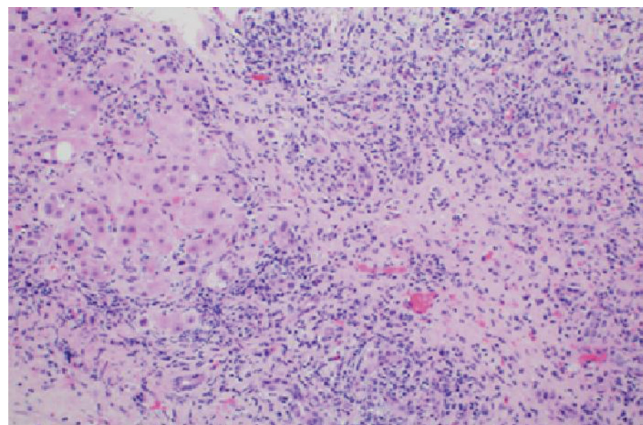
**Figure 1:** Portal inflammatory infiltrate composed of lymphocytes and plasma cells.

## Discussion

Viruses are suggested to play a role in triggering autoimmune hepatitis. AIH due to viral pathogenesis have been debated and several proposed theories have emerged. One proposed theory that has been gaining support which is considered the main viral pathogenesis is molecular mimicry. The theory suggests that environmental triggers such as viruses along with failure of immune tolerance and a genetic predisposition, induces T-cell mediated immune attacks against the liver antigens leading to a progressive necroinflammatory and fibrotic process in the liver.<sup>[4]</sup>

The relationship is between the genetics of the individual and the autoimmune process at the molecular level. This specific process involves antigen, the major histocompatibility complex (MHC), and T cell receptor (TCR). Moreover, there is research suggesting cross-reactivity between ALKM-1 against homologous regions of cytomegalovirus (exon CMV130-135). Since the CMV IgM and IgG ab titers were positive in this patient. LKM1 antibody may arise from recognizing the exon 130-135 on the cytomegalovirus, which is seen in 4% of the cases. However, this antibody also recognizes the major epitope of CYP2D6 of P450 system (amino acids 254-271), causing this cross-reactivity.<sup>[1, 5]</sup> Manns et al.<sup>[5]</sup> suggested that reactivity to the major epitope LKM1 is also seen in response to amino acids 310-324 of the envelope region E1 of hepatitis C (HCV) and amino acids 156-170 of the immediate early protein Ie175 the herpes simplex virus type 1 (HSV1). LKM1 antibodies are found in up to 10% of patients with hepatitis C virus infection and appear to correlate with increased disease severity and adverse reactions to interferon.<sup>[4, 5]</sup> Given the patient was HCV and HSV negative, these are not viable options.

Treatment is generally aimed at decreasing the inflammatory process. A scoring system has been implemented to determine the prognosis of AIH. In 1993 a scoring system was done by the international panel and revised in 1999. According to



**Figure 2:** Portal-based chronic inflammation and fibrosis. There is interface hepatitis.

the revised original scoring system of the international autoimmune hepatitis group pretreatment score of 15 points or higher is indicative of definitive AIH with a sensitivity of 95% and specificity of 97%,<sup>[5]</sup> in our specific case the calculated score of the patient was 41. More recently, a simplified scoring system has been developed based on presence and level of autoantibody expression by indirect immunofluorescence, serum Ig G concentration, compatible or typical histological features and the absence of viral markers. Moreover, 40% of patients with untreated severe disease died within 6 months of diagnosis and survivors frequently developed cirrhosis, esophageal varices and subsequent hemorrhage. Three randomized, control trials have demonstrated that patients with serum AST levels 10 times upper limit normal (ULN) or more than 5 times ULN with serum  $\gamma$ -globulin level more than two-fold ULN, have a high mortality (60% at 6 months) if untreated.<sup>[5]</sup> This patient did not meet this criteria; however, did have a liver biopsy which showed heavy infiltration with lymphoplasmacytic inflammatory cells (image 2), interface hepatitis (image 1), bridging necrosis and fibrosis, which is associated with a 5-year mortality of 45% and an absolute indication for corticoid steroid treatment. Randomized controlled treatment trials established that prednisone alone or in combination with azathioprine improved symptoms, laboratory tests, histological findings, and immediate survival. These studies led to the acceptance of immunosuppressive regimens as the standard in treatment.<sup>[5]</sup>

AIH has a heterogeneous and fluctuating nature, leading to marked variability in its clinical manifestations. Its spectrum ranges from asymptomatic patients to those with considerable and sometimes debilitating symptoms, and even those with acute liver failure. What is poorly understood is the pathogenesis. Predisposed individuals are directed toward genes encoding human leukocyte antigens (HLA). Classical (type 1) autoimmune hepatitis (AIH) is strongly associated with the HLA haplotype A1, B8, DR3 and with DR3 and DR4 allotypes.<sup>[1]</sup> HLA-DR3 associated disease is more commonly found in the early onset severe form of disease (while,) HLA D4 is more common in Caucasians with late onset of disease and is associated with higher incidence of extra hepatic manifestations with a better response to corticosteroids.<sup>[6-9]</sup> We must include viral etiology in the differential for patients who have AIH because there is a combination of genetic and environmental exposures including infectious agents such as CMV. Cross reactive theories such as molecular mimicry, has been gaining strong experimental support. However, research on exact mechanisms can help guide clinical strategies for prevention and even allow therapy.

In regards to the present case, immunologically the patient had a positive ANA, positive anti-smooth muscle Ab, hypergammaglobulinemia and had an AIH international score of 41. Histologically, the biopsy showed characteristic AIH findings such as confluent necrosis with collapsed areas heavily infiltrated by lymphoplasmacytic inflammatory cells. Plasma cells occur in groups and severe interface hepatitis noted. The remaining lobules show numerous foci of necroinflammation and cholestasis. Trichrome stain shows portal fibrosis

with fibrous septa that bridge and partially enclose nodules. With the above mentioned findings plus positive CMV IgG and IgM ab titers, led to a final diagnosis of AIH Type 1 and reveals a possible link between viruses more specifically CMV and autoimmune hepatitis. More clinical observations and evidence are needed to define a possible role for viruses such as CMV in the pathogenesis of AIH.<sup>[1, 3]</sup>

## Conclusion

CMV is considered to play a role in triggering AIH. It is difficult to diagnose AIH because its presentation can be acute, severe, asymptomatic or chronic. Diagnosis requires multiple findings and exclusions of similar diseases. When excluding, make sure viral etiologies are part of the differential, which in this case is CMV. If a trigger is required to set off a sequence of events leading to AIH in these predisposed individuals, viruses are among the most likely candidates.

## References

1. Vento S, Cainelli F. Is there a role for viruses in triggering autoimmune hepatitis? *Autoimmun Rev.* 2004;3(1):61–9.
2. Krawitt EL. Autoimmune hepatitis. *N Engl J Med* 2006; 354:54.
3. Toyoda-Akui, Megumi, et al. Association of an overlap syndrome of autoimmune hepatitis and primary biliary cirrhosis with cytomegalovirus infection. *Int J Gen Med* 2011;4: 397.
4. Bogdanos DP, Choudhuri K, Vergani D. Molecular mimicry and autoimmune liver disease: virtuous intentions, malign consequences. *Liver* 2001;21:225–32.
5. Manns MP, Czaja AJ, Gorham JD et al. Practice guidelines of the American association for the study of liver diseases. Diagnosis and management of autoimmune hepatitis. *Hepatology* 2010;51: 2193–213.
6. Donaldson PT, Albertini, et al. In: *Immunogenetic studies of autoimmune hepatitis and primary sclerosing cholangitis*. Elsevier Science, Krawitt EL, Wiesner RH, Nishioka M (Eds), Amsterdam 1998.
7. Montano L, Aranguibel F, Boffil M, Goodall AH, Janossy G, Thomas HC. An analysis of the composition of the inflammatory infiltrate in autoimmune and HBV induced chronic liver disease. *Hepatology* 1983;13:292–7.
8. Donaldson PT. Genetics of autoimmune and viral liver diseases; understanding the issues. *J Hepatol* 2004;41(2):327.
9. Doherty DG, Donaldson PT, Underhill JA, Farrant JM, Duthie A, Mieli-Vergani G, McFarlane IG, Johnson PJ, Eddleston AL, Mowat AP. Allelic sequence variation in the HLA class II genes and proteins in patients with autoimmune hepatitis. *Hepatology* 1994;19(3):609.

**How to cite this article:** Vyas N, Companioni RC, Nguyen J, Alkhawa H, Sogomonian R, Patel I, Baum I, Walfish A. Cytomegalovirus triggering autoimmune hepatitis: case report and literature review. *Int J Med Sci Public Health* 2017;6:220-222

**Source of Support:** Nil, **Conflict of Interest:** None declared.